

15

LAPAROSCOPIC OVARIECTOMY

Andrea M. Pievaroli

**Indications**

- Removal of both ovaries for suppression of the estrous cycle
- Prevention of diseases of the reproductive system
- Treatment of ovarian pathologies
- Treatment of ovarian remnant syndrome

Contraindications

- Cardiovascular and pulmonary diseases
- Congenital diaphragmatic defects
- Uterine pathologies (cases requiring ovariohysterectomy/laparoscopic ovariohysterectomy)

Laparoscopic ovariectomy is the endoscopic surgical procedure most frequently performed in dogs. Even in cats, it has become an alternative to traditional ovariectomy and is increasingly offered to cat owners. Laparoscopic sterilization is becoming widely accepted by pet owners, who often request a minimally invasive approach with less postoperative pain and a faster recovery for other surgeries on their pets. The advantages of laparoscopic ovariectomy have been widely demonstrated through various scientific studies and have led to an ever-increasing number of veterinary clinicians being able to perform this procedure. It can be said that this technique is now considered the gold standard for female dog sterilization. Less pain, less discomfort, and fewer complications are indisputable advantages. Dogs undergoing laparoscopic ovariectomy have a significantly lower pain score and increased postoperative activity levels compared to dogs spayed with the traditional technique.

The first laparoscopic procedure for the sterilization of dogs and cats reported in the literature dates back to 1985. The authors chose a minimally invasive laparoscopic approach to perform occlusion of the uterine horns by electrocoagulation, without removing the ovaries. The first laparoscopic procedures for ovary removal in the dog were described by European veterinary schools in the 1990s. In the 2000s, the technique was progressively perfected as the instruments and equipment for minimally invasive surgery—until then used exclusively in human medicine—became less expensive and more easily accessible.

While ovariectomy is mainly indicated to suppress the estrous cycle, avoid reproduction, and prevent diseases of the reproductive system, it can also be performed for the treatment of ovarian pathologies.

Since the introduction of the laparoscopic technique for dog and cat sterilization, the advisability of performing an ovariectomy (OVE) over removing the ovaries and the uterus (ovariohysterectomy, OVH) has been called into question. This topic has often been contentious in the veterinary literature. European veterinary surgeons have been performing OVE for years without any complications affecting the uterine tract left in situ. Veterinary surgeons in the United States, on the other hand, have historically been taught to perform OVH to reduce the risk of pyometra or neoplasia affecting the uterus. However, studies with long-term follow-up periods have shown no evidence of pyometra or of a higher incidence of uterine neoplasia (approximately 0.003%) in ovariectomized patients. For this reason, and considering the ease of the procedure, if there are no indications for the removal of the uterus, laparoscopic sterilization of dogs is usually done everywhere by removing only the ovaries (lapOVE).

The risk of acquired urinary incontinence (AUI) following lapOVE does not differ from that when OVE is performed by laparotomy. A study published in 2019 compared the prevalence rates and severity of AUI between dogs spayed with laparoscopic and open laparotomy approaches and concluded that the minimally invasive approach does not reduce the likelihood of this complication.

LapOVE can be performed in patients of all breeds, ages and sizes, with some limitations in too small or excessively obese patients. Each patient can be considered a potential candidate for laparoscopic sterilization. Technical difficulties and surgical times can be influenced by the body conformation, the state of nutrition (body condition score, BCS), and by the amount of adipose tissue located in correspondence with the ovary. It is essential to acquire experience and skills in lapOVE to be able to perform, when necessary, the removal of the uterus (lapOVH), a topic that will be discussed in Chapter 17.

The first laparoscopic ovariectomy of dogs was reported in 1993 by S. Thiele, G. Kelch, et al.

DESCRIBED SURGICAL PROCEDURES

Various techniques have been described for the laparoscopic removal of the ovaries in dogs and cats, involving the use of one, two or three ports. The choice depends on the surgeon's personal preferences and the surgical difficulty in the patient. In the early years, when lapOVE procedures began, the operative ports were placed transversely to the midline, on a left and right paramedian line. This arrangement was soon replaced by positioning ports only on the midline, for greater advantages in performing the procedure.

In the veterinary literature, scientific studies published since 2009 have compared the various techniques to evaluate the advantages and disadvantages in their execution and the benefits for the patient in the postoperative period. The first reported one-port technique was performed using a particular 10 mm telescope with an operating channel (operating laparoscope) placed 1–2 cm caudal to the umbilicus. Endoscopic forceps and sealing devices were inserted parallel to the scope to perform the OVE. Although this technique has been shown to be safe and feasible even in small size patients, there is no triangulation for the graspers and more experience and skills are required to deal with any possible intraoperative complications. A paper published in 2011 compared the one-, two-, and three-port techniques to evaluate surgical time and severity of postoperative pain (using a modified Melbourne Pain Scale and palpation of surgical sites) in dogs undergoing lapOVE. The conclusion was that there were no significant differences in complication rates between the groups, but there were significantly lower pain score levels with the two-port technique than with the three-port technique. In addition,

there was a similar median pain score between dogs in which two instrument cannulas were used and those in which a single cannula was used. In recent years, another single-access technique has taken hold and is commonly used today, which consists in the use of single-incision multiport devices to introduce more operative instruments in the same port (single-incision laparoscopic surgery [SILS] and similar single-port devices).

PATIENT PREPARATION AND POSITIONING

The patient should be fasted for 10–12 hours before surgery; water is allowed. The bladder should be emptied before the procedure to allow better visualization into the pelvic area. The abdomen is widely clipped; the surgical clip should extend cranially to the xiphoid process and include the entire vulva caudally. Even if the access is limited to the midline, wide clipping of the hair must also be performed laterally. This is preferable in case of conversion (as a rule for each laparoscopic procedure) and in case of percutaneous needle insertion for the two-port technique.

The patient is placed in dorsal recumbency and the skin is aseptically prepared before draping (**Fig. 1**). It is preferable to use a tilting table (better if motorized and remotely controlled) to easily reposition the patient during the different steps of the procedure (**Fig. 2**). Alternatively, positioners supplied by some companies can be used. They are placed on the operating table and allow the patient to be tilted laterally (**Fig. 3**).

In addition to lateral inclinations to better visualize the ovaries, it can be useful to tilt the table in a Trendelenburg position to displace the spleen cranially.

Some fundamental structures that should be identified during lapOVE are indicated in **Figure 4**. Attention must be paid to effective coagulation of vascular structures (ovarian artery and vein, uterine branch of ovarian artery and vein), which may be responsible for bleeding following ovary removal. In some obese patients, or if the lateral tilt of the table is not adequate, it may be useful to follow the round ligament to locate the ovary.

OPERATING ROOM LAYOUT

The endoscopy tower with all devices can be placed at the patient's foot or head, depending on the size of the operating room. The important thing is to leave enough space for the

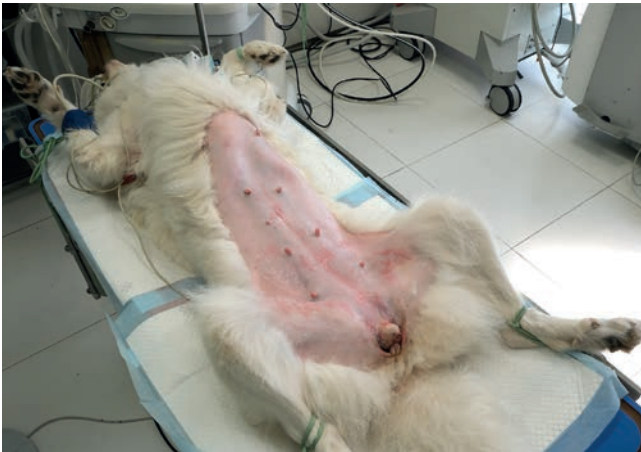

FIGURE 1. Dog in dorsal recumbency. The abdomen is widely clipped.



FIGURE 2. For laparoscopic ovariectomy, it is preferable to use a motorized tilting surgical table with a remote control.



FIGURE 3. Example of an electrical tilt device positioner. Design by Dr. Bernardino Izzo (Italy).

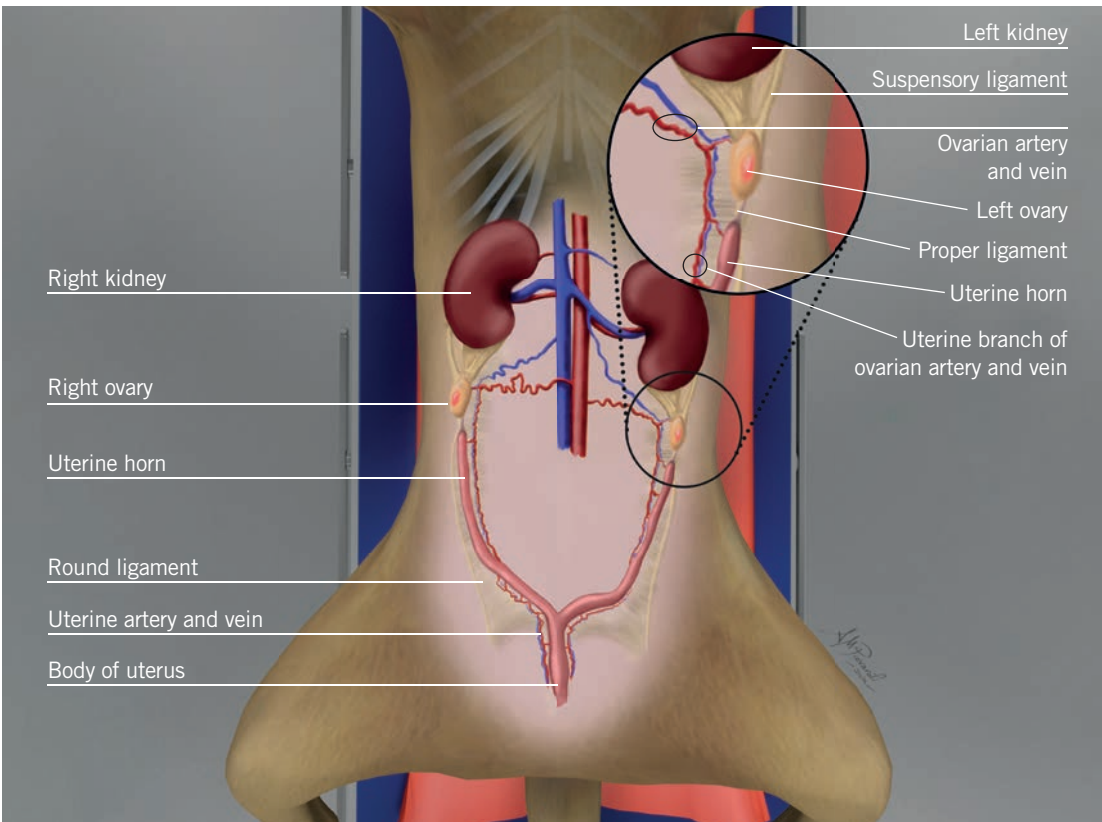


FIGURE 4. Female dog reproductive system.

SECTION II. LAPAROSCOPY

surgeon and the assistant to move from one side of the table to the other. If the monitor is fixed on the tower, it is usually placed at the caudal end of the table (**Fig. 5**).

However, it is preferable to be able to move the monitor during the procedure to follow the surgeon's change of position and comply with the ergonomic principles of minimally invasive endoscopic surgery. This may be possible using a ceiling or boom-mounted monitor, a monitor installed on a mobile tower, or two monitors arranged on each side of the patient. The anesthesia machine is placed near the patient's

head. The instrument table is placed caudolateral to the table, on the same side as the surgeon. To perform the OVE, the surgeon and their assistant position themselves on the opposite side in relation to the ovary to be removed (**Fig. 6**).

The following procedures are described below:

- A. Two-port ovariectomy technique
- B. Three-port ovariectomy technique
- C. Single-port laparoscopic ovariectomy technique (J. Runge and J. Becker)

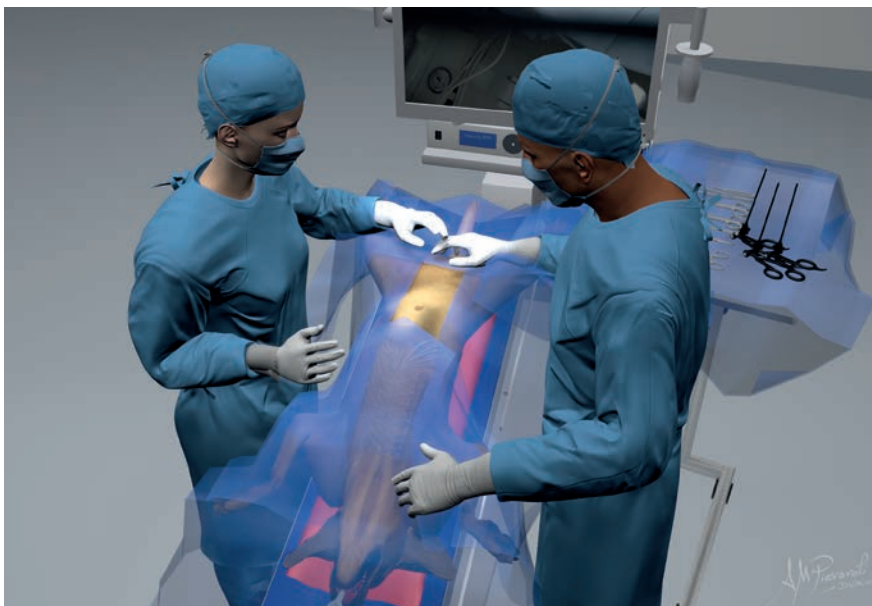

FIGURE 5. Operating room layout for laparoscopic ovariectomy. Initial setup for port placement.

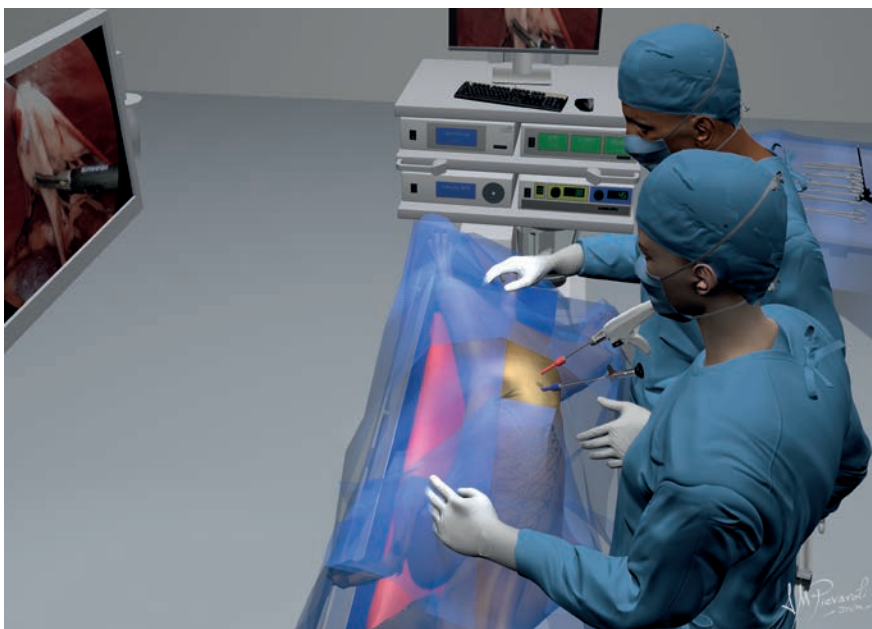


FIGURE 6. Layout during the ovariectomy: the table is tilted laterally; the surgeon and the assistant are positioned on the opposite side in relation to the ovary to be removed.

A TWO-PORT OVARIECTOMY

Two-port ovariectomy is currently the most commonly used technique and has the advantage of being very minimally invasive, as reported in the literature. Ports are placed in the midline, 1–2 cm cranial and 2–4 cm caudal to the umbilicus, depending on the size of the patient. The cranial cannula is used for the telescope, while the caudal cannula is used for the operative instruments. The distance between the trocars must be adequate for correct triangulation around the ovary. The ovary to be removed is kept suspended in the abdomen using a suture inserted percutaneously with a needle. This solution avoids

using the third cannula, thereby reducing the invasiveness of the surgery. Some surgeons use a specific OVE hook instrument (Karl Storz Endoscopy) instead of the suture. After suspending the ovary to be removed, coagulation and cutting are performed (**Video 1**).



VIDEO 1. Two-port laparoscopic ovariectomy.

Instruments

On the table:

- Standard abdominal surgical pack
- Telescope 5 mm – 30°
- Two 5 mm cannulas (or one 5 mm cannula + one 10 mm cannula)
- Grasping forceps
- Large-gauge (usually 1 or 0) suture swaged on a needle
- Vessel-sealing device

Ready to use:

- Endoscopic cannula for aspiration/irrigation
- Third cannula to switch to the three-port technique

Minilaparoscopy 3 mm set (Fig. 7) for dogs and cats weighing less than 3–4 kg:

- Standard abdominal surgical pack
- Telescope 2.7 mm – 30°
- Two 3 mm cannulas
- Grasping forceps
- Endoscopic scissors
- A suture swaged on a needle
- Bipolar coagulation forceps

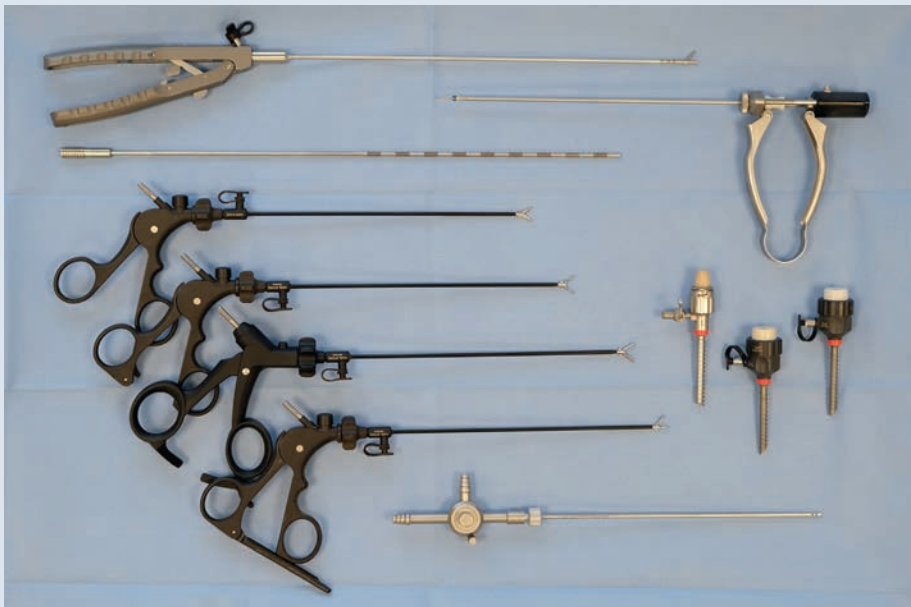

FIGURE 7. Minilaparoscopy set for patients weighing less than 3–4 kg.

PORT PLACEMENT (Fig. 8)

- T1, on the midline, 1–2 cm cranial to the umbilicus
- T2, on the midline, 3–6 cm caudal to the umbilicus

PROCEDURE

- Placement of the first trocar (cranial [T1] or caudal [T2]) is based on the surgeon's preferences. It is advisable to tilt the table into a Trendelenburg position to perform this step of the procedure. The author prefers to use threaded canulas (Storz Endotip) to prevent slippage from within the peritoneum.
- A pneumoperitoneum is established using the surgeon's preferred technique; the author uses the Ternamian or a modified Hasson technique. After the first port has been placed and the pneumoperitoneum achieved, the 5 mm telescope is inserted and a first exploration of the abdomen is performed to check for any evidence of iatrogenic trauma caused by placement of the first cannula.
- The falciform ligament, which could prevent correct vision and cloud the lens of the telescope, can often be found in this area of the peritoneum (**Fig. 9**). It is necessary to screw the port deeper to find the right inclination to overcome the ligament.

Tips

To avoid crossing the falciform ligament, the port can be inserted slightly lateral (1–2 cm) to the midline.

- Under endoscopic vision, the second cannula is inserted for a correct triangulation around the ovary to be removed. It is preferable to use the cranial port for the telescope and the caudal port for the instruments (**Fig. 10**). Some authors prefer to reverse the tools (telescope in the caudal port and forceps in the cranial port).
- The surgeon performs the surgery on the contralateral ovary with respect to their position.
- For better visualization of the ovary, especially in obese patients, in the presence of meteoric intestinal loops or splenomegaly, the patient should be tilted to an oblique position (at least 45°) to displace the organs by gravity and facilitate manual surgical procedures (**Fig. 11**). Some authors prefer to place the patient in lateral recumbency instead of in an oblique position.

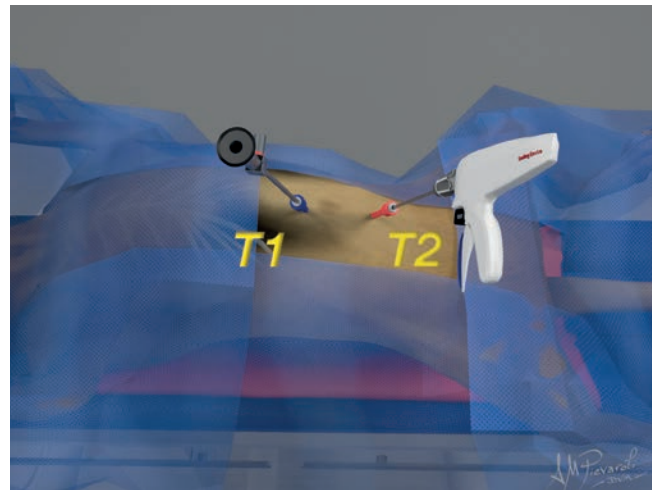


FIGURE 8. Port placement for two-port ovariectomy.

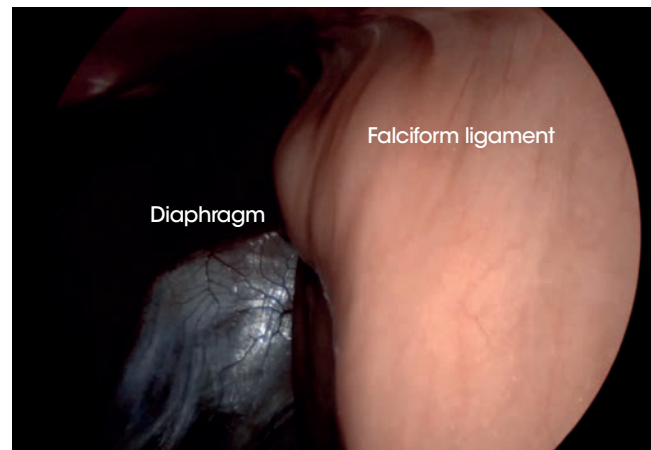


FIGURE 9. The falciform ligament can often be found in umbilical area. This could prevent correct vision and cloud the lens of the telescope.




FIGURE 10. Image of the operating field for two-port laparoscopic ovariectomy.

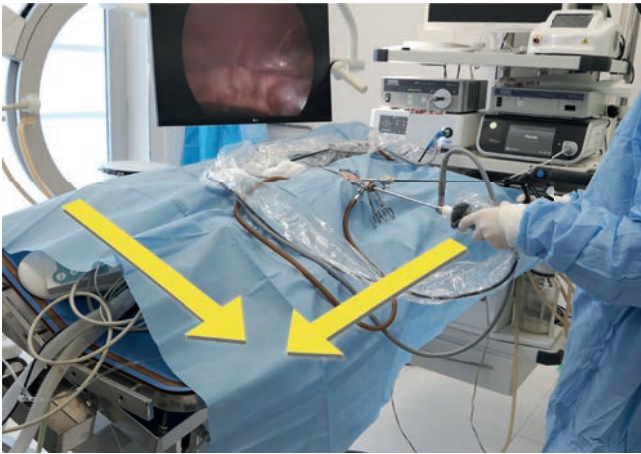


FIGURE 11. The table should be tilted laterally, at least 45°. Use a Trendelenburg and oblique position to displace the organs by gravity.

- Atraumatic forceps or a blunt probe are used to move the organs and locate the ovary and uterine horn, which are located caudal to the kidney. Forceps are then used to grasp the proper ligament and elevate the ovary to visualize the kidney, the suspensory ligament of the ovary and the ovarian vasculature (**Fig. 12**).
- Palpating the abdomen from the outside, a point on the wall is identified in correspondence with the ovary. Then, under direct endoscopic vision, a suture is inserted percutaneously with a large size half-circle needle (**Fig. 13a**). The needle is passed through the proper ligament or the cranial uterine horn, avoiding the ovarian artery and vein, and then outside of the body wall again (**Fig. 13b**).
- After anchoring the ovary with suture thread, the forceps are removed from the port.
- The two ends of the suture outside the body wall are pulled to elevate the ovary and placed under tension with Klemmer forceps or a hemostat (**Fig 14**).
- A vessel-sealing device (VSD) is introduced in the caudal port. The suspensory ligament is usually sealed and transected first. Then, the kidney is identified and the omentum or other organs that may interfere are moved. The jaws of the forceps are used to seal and dissect the mesovarium (including the ovarian artery and vein) and suspensory ligament, taking care to remain at a sufficient distance from the ovary (**Fig. 15**).

Two-port minilaparoscopy with 3 mm cannulas: In small dogs and cats, 3 mm bipolar forceps should be used to coagulate vessels and tissues. The small endoscopic scissors are then introduced to dissect the ovaries free (**Fig. 16**) (**Video 2**).

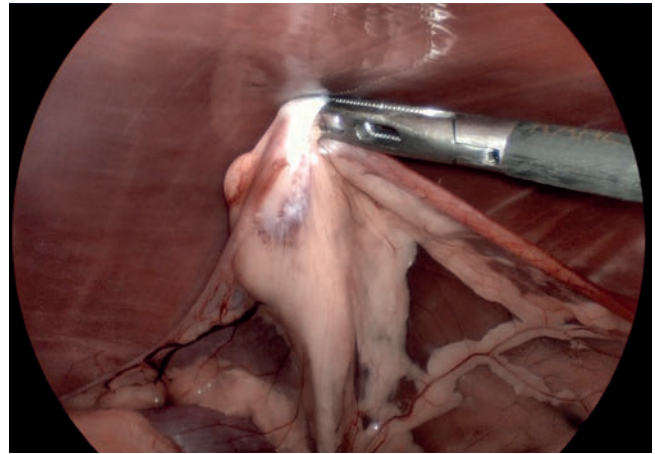


FIGURE 12. The proper ligament is grasped to elevate the ovary (the left ovary is shown in the figure).

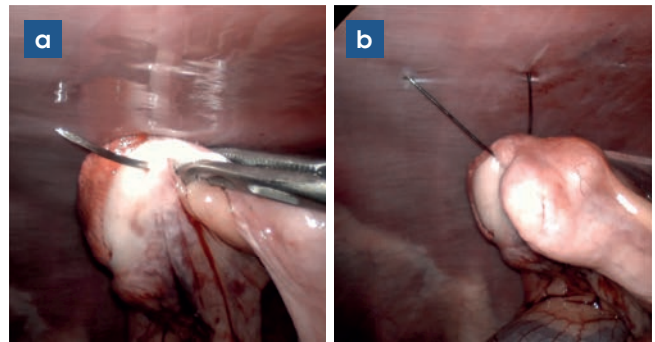


FIGURE 13. A suture is inserted percutaneously with a large size half-circle needle and passed through the proper ligament.

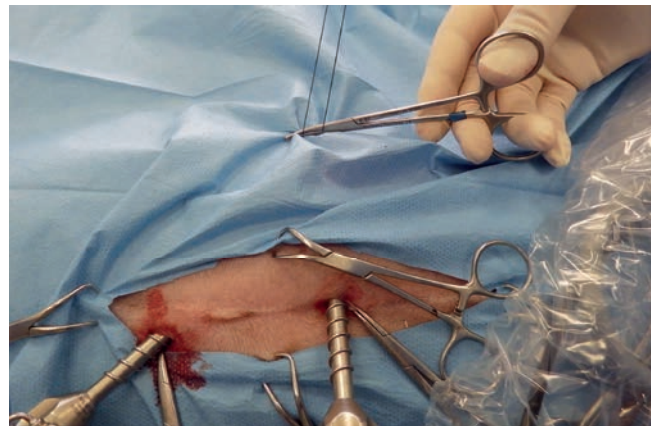


FIGURE 14. The two ends of the suture are clamped outside using a hemostat.



VIDEO 2. Two-port minilaparoscopic ovariectomy in a cat.

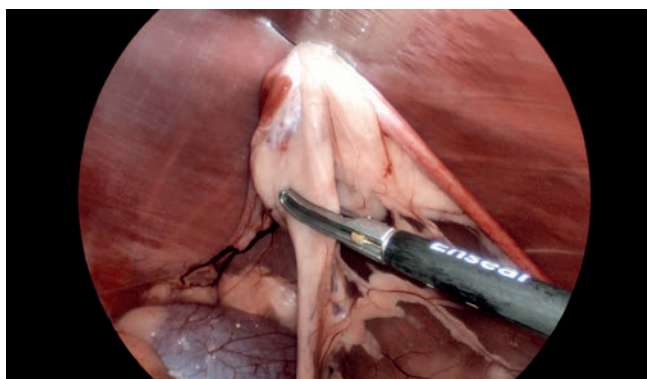


FIGURE 15. Use of a vessel-sealing device to grasp the suspensory ligament between the kidney and ovary to perform the resection.

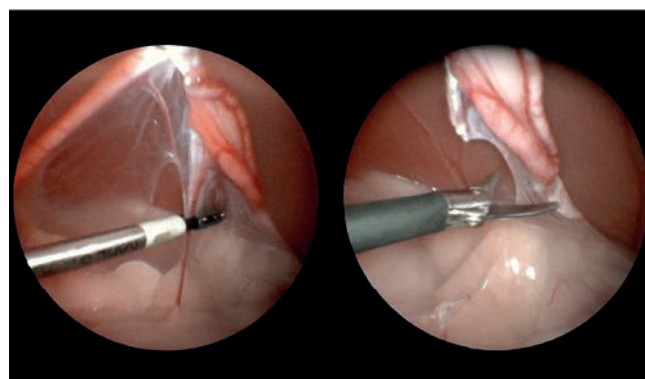


FIGURE 16. Two-port minilaparoscopy. a) Use of 3 mm bipolar forceps to coagulate the suspensory ligament. b) The ovaries are then dissected free with scissors.

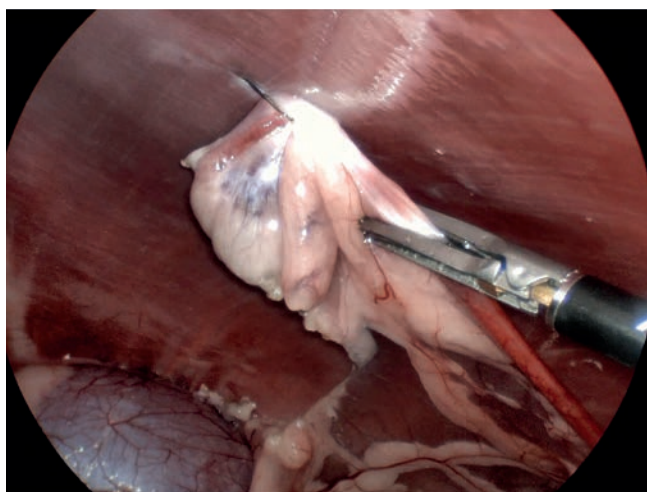


FIGURE 17. The jaws are closed and the vessel-sealing device operated to perform resection of the uterine horn.

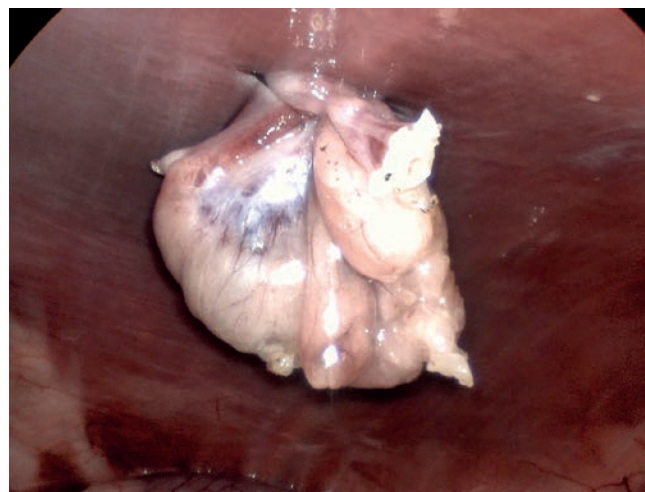


FIGURE 18. The dissected ovary is still anchored by the suture to the body wall.

- Then, using the VSD, the first part of the uterine horn is grasped and the resection is performed including the mesometrium, until the ovary is completely isolated (**Fig. 17**). The ovary must remain anchored to the body wall by the suture (**Fig. 18**).
- The surgeon should carefully check for any evidence of bleeding from the dissected vessels before tilting the table in the opposite position to remove the contralateral ovary.
- At this point, the surgeon and the assistant should move to the opposite side and the table should be tilted laterally towards them.
- The surgeon then performs the same procedure to remove the second ovary (**Fig. 19**).
- After the procedure has been completed on both sides, the table is tilted back to the initial neutral position. It is preferable for the surgeon and the assistant to be placed on each side of the table.

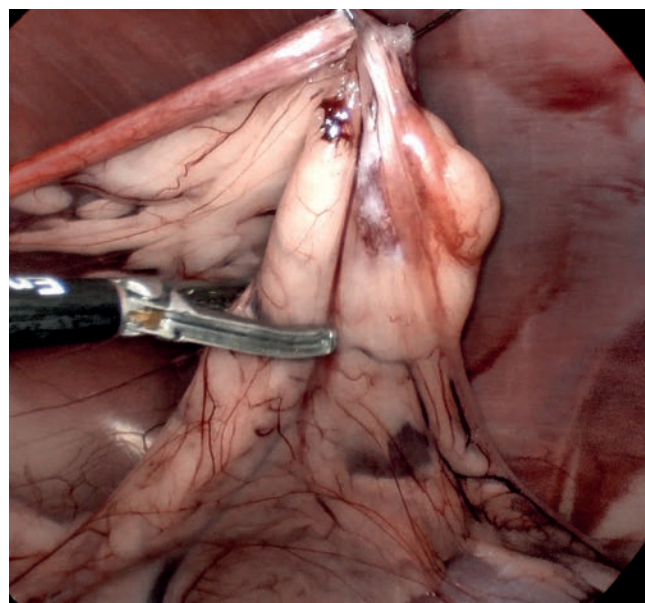


FIGURE 19. Endoscopic view of the second ovary (right ovary).

- The forceps are inserted in the caudal cannula to grasp an ovary and bring it to the port. The suture is released and the cannula is removed while pulling the ovary out of the abdominal cavity (**Fig. 20**). In medium and large dogs, the ovary is usually larger than the port size. In these cases, it is necessary to slightly widen the portal incision.

Tips

In large dogs or in case of ovaries surrounded by fat, the surgeon can use a 10 mm cannula (for the caudal port) with an adapter to use 5 mm instruments and have a larger size of incision to extract the tissues.

- Then, the port is repositioned and the pneumoperitoneum determined again. In case of CO₂ leak, a hemostat can be used to temporarily close the skin around the port.

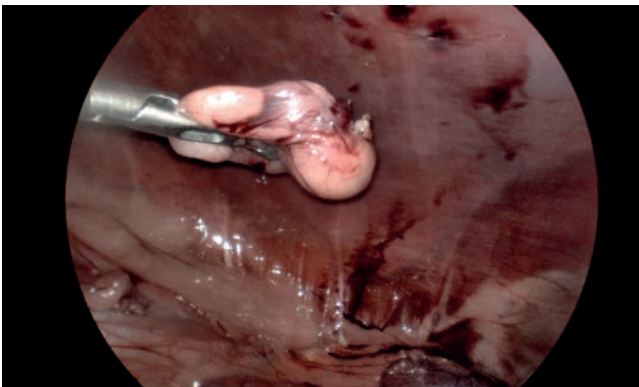


FIGURE 20. The ovaries are grasped and extracted through one of the portal incisions.

- The second ovary is removed and an exploration of the abdomen performed to exclude active bleeding. The abdomen is then deflated and the ports removed.
- Finally, the small incisions in the abdominal fascia and the skin at the port sites are closed routinely.

B THREE-PORT OVARIECTOMY

The use of three ports to perform lapOVE is now less common than it was a few years ago and is mainly considered when the surgery can be more challenging. For example, in very obese patients or in the presence of some ovarian pathologies, the use of two “hands” can facilitate the laparoscopic procedure. The use of a second pair of grasping forceps replaces the suture passed percutaneously to suspend the ovary. In addition, in cases of two-port lapOVE complications (e.g., severe bleeding), it may be necessary to add a third cannula to deal with the problem.

Ports are placed in the midline, cranial and caudal to the umbilicus. The central cannula is used for the telescope, while the cranial and caudal cannulas are used for the operative instruments. The distance between the trocars must be appropriate for correct triangulation around the ovaries. The grasping forceps are used to locate and suspend the ovary, while the uterine horn is resected using the VSD in the other port (**Video 3**).



VIDEO 3. Three-port laparoscopic ovariectomy.

Instruments

On the table:

- Standard abdominal surgical pack
- Telescope 5 mm – 30°
- Three 5 mm cannulas (or two 5 mm cannulas + one 10 mm cannula)
- Grasping forceps
- Vessel-sealing device

Ready to use:

- Endoscopic cannula for aspiration/irrigation

Minilaparoscopy 3 mm set for dogs and cats weighing less than 3–4 kg:

- Standard abdominal surgical pack
- Telescope 2.7 mm – 30°
- Three 3 mm cannulas
- Grasping forceps
- Endoscopic scissors
- Bipolar coagulation forceps

PORT PLACEMENT (Fig. 21)

- T1, on the midline, 1–2 cm caudal to the umbilicus
- T2, on the midline, 3–5 cm caudal to T1
- T3, on the midline, 3–5 cm cranial to T1

PROCEDURE

- Placement of the first trocar (cranial, caudal or central) is based on the surgeon's preferences. It is advisable to tilt the table into a Trendelenburg position to perform this step of the procedure. The author prefers the use of threaded cannulas (Storz Endotip) to prevent slippage from within the peritoneum.
- A pneumoperitoneum is established using the surgeon's preferred technique; the author uses the Ternamian or a modified Hasson technique. After the first port has been placed and the pneumoperitoneum achieved, the 5 mm telescope is inserted and a first exploration of the abdomen is performed to check for any evidence of iatrogenic trauma caused by placement of the first cannula.
- Under endoscopic vision, the second and the third cannulas are inserted following the instructions on positioning for a correct triangulation around the ovaries. To get a more natural view, it is preferable to use the central port for the telescope and the cranial and caudal ports for the instruments (**Fig. 22**).
- The falciform ligament, which could prevent correct vision and cloud the lens of the telescope, can often be found when introducing the central port (see **Fig. 9**). It is necessary to screw the port deeper to find the right inclination to overcome the ligament.

Tips

To avoid crossing the falciform ligament, the port can be inserted slightly lateral (1–2 cm) to the midline.

- The surgeon performs the procedure on the contralateral ovary with respect to their position.
- For better visualization of the ovary, especially in obese patients, in the presence of meteoric intestinal loops or splenomegaly, it is necessary to tilt the patient in an oblique position (at least 45°) to displace the organs by gravity and facilitate manual surgical procedures. Some authors prefer to place the patient in lateral recumbency instead of in an oblique position.

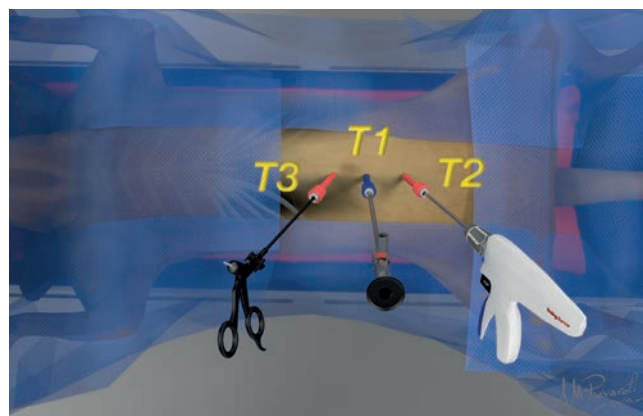


FIGURE 21. Portal placement for three-port ovariectomy.

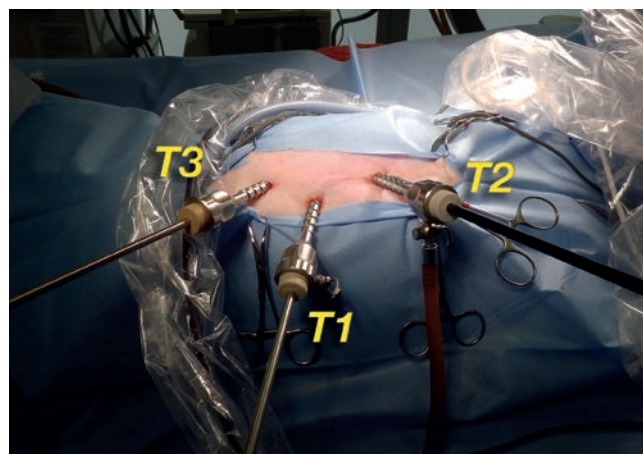


FIGURE 22. Image of the operating field for three-port laparoscopic ovariectomy.

- Atraumatic forceps or a blunt probe are used with both hands to better move the organs and locate the ovary and uterine horn, which are located caudal to the kidney. Using the forceps in the cranial port, the proper ligament is grasped and the ovary is elevated to visualize the kidney, the suspensory ligament of the ovary and the ovarian vasculature.
- A VSD is introduced in the caudal port. The suspensory ligament is usually sealed and transected first. Then, the kidney is identified and the omentum or other organs that may interfere are moved. The jaws of the forceps are used to seal and dissect the mesovarium (including the ovarian artery and vein) and the suspensory ligament, taking care to remain at a sufficient distance from the ovary (**Fig. 23**).

Minilaparoscopy with 3 mm cannulas: In small dogs and cats, the surgeon should use 3 mm bipolar forceps to coagulate vessels and tissues. The small endoscopic scissors are then introduced to dissect the ovaries free.

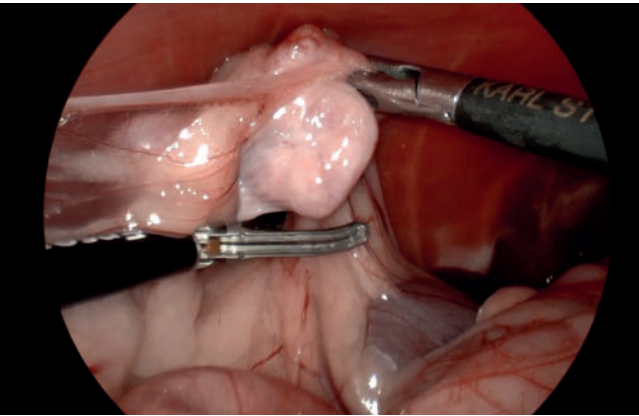


FIGURE 23. The forceps are used to grasp the proper ligament and elevate the ovary. The vessel-sealing device is activated to dissect the suspensory ligament (the right ovary is shown in the figure).

- Then using the VSD, the first part of the uterine horn is grasped and the resection is performed including the mesometrium, until the ovary is completely isolated. The ovary must immediately be removed from the abdomen through one of the ports. In medium and large dogs, the ovary is usually larger than the portal size. In these cases, it is necessary to slightly widen the portal incision.

Tips

In large dogs or in case of ovaries surrounded by fat, the surgeon can use a 10 mm cannula with an adapter to use 5 mm instruments and have a larger size of incision to extract the tissue.

- Then, the port is repositioned and the pneumoperitoneum determined again. In case of CO₂ leak, a hemostat should be used to temporarily close the skin around the port.
- The surgeon should carefully check for any evidence of bleeding from the dissected vessels before tilting the table to the opposite position to remove the contralateral ovary.
- At this point the surgeon and the assistant should move to the opposite side. The table is then tilted laterally towards them.
- The surgeon then performs the same procedure to resect the second ovary. The second ovary should be removed from the abdomen through one of the portal incisions.
- After the procedure is completed on both sides, the table is tilted back to the initial neutral position. It is preferable that the surgeon and the assistant are also placed on each side

of the table. An exploration of the abdomen should be performed to exclude active bleeding. The abdomen is then deflated and the ports removed.

- Finally, the small incisions in the abdominal fascia and in the skin at the portal sites are closed routinely.

If ovarian pathologies are present, it will be necessary to perform an OVH. In most cases, this procedure can also be performed laparoscopically, as will be described in Chapter 17.

C SINGLE-PORT LAPAROSCOPIC OVARIECTOMY

Jeffrey J. Runge, Joshua G. Becker

Instruments

- Standard surgery set
- Telescope 5 mm – 30°
- Single-incision port device
- A bipolar VSD appropriate for the patient size
- Articulating laparoscopic grasping forceps (such as the SILS Clinch Graspers)

PORT PLACEMENT (Fig. 24)

- T1, T2, T3. The port is placed in standard fashion at the level of the umbilicus.

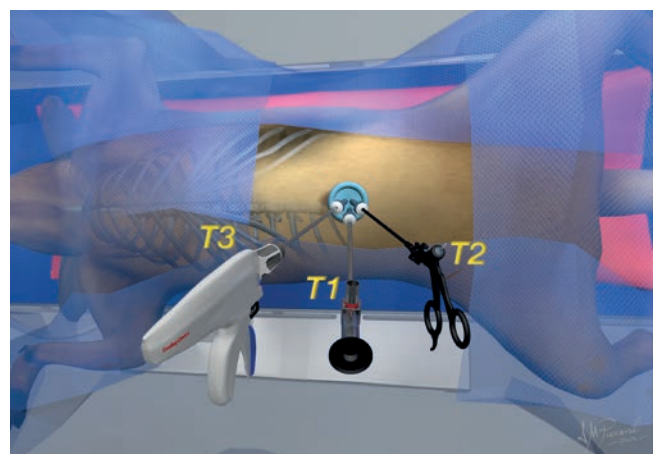


FIGURE 24. Single-port placement for laparoscopic ovariectomy.

PROCEDURE

- After the port has been placed (**Fig. 25**) and a pneumoperitoneum established, the scope is inserted and the abdomen is surveyed in standard fashion, checking for anatomical landmarks and identifying the visible anatomy. Care must be taken to avoid and check for evidence of iatrogenic trauma secondary to port placement.
- The patient's position on the operating table can then be manually adjusted into a modified dorsal-lateral recumbency to better visualize the contralateral ovary (e.g., if first removing the left ovary, the patient would be adjusted into a modified right lateral recumbency). If the surgeon has a surgical table with a lateral tilt function, this can be utilized on its own or concurrently to help facilitate this process. The patient's abdomen can also be gently shaken after positioning to adjust the omentum and other potentially obstructive viscera, thus improving visualization of the ovaries.
- The uterine horns and relevant anatomy are identified. The articulating forceps or other blunt probing instruments can be used to manipulate and position tissue for better visualization.
- With the articulating grasper, a 90° positional bend at the distal third of the instrument can be created with the tip deflecting toward the ovary.
- The proper ligament is then grasped using the forceps, which can be locked in a closed position, and the proper ligament is elevated to visualize and isolate the ovarian vasculature, the uterine horn, and the suspensory ligament (**Fig. 26**). The tissue is suspended with the bent portion of the articulating instrument still deflected.
- With the ovary and relevant anatomy isolated, the VSD is then used to carefully seal and cut the ovarian pedicle, the suspensory ligament and the most distal portion of the uterine horn (**Fig. 27**). Particular care and attention to hemostasis should be paid in overweight patients or patients with excessive fat at the level of the ovarian vasculature.
- Once the ovary and associated tissue have been dissected from their attachments, the ovary can be partially retracted from the laparoscopic field to better visualize the dissection site and monitor for any delayed bleeding (**Fig. 28**). Care should be taken to ensure that the ovary is properly grasped prior to dissection and retraction from the visual field to minimize the risk of inadvertent dropping in the abdominal cavity.
- If the SILS port is used, the port should be removed from the incision along with the forceps grasping the ovary in order to remove the ovary.

- It is recommended to inspect the ovary to check for completeness of dissection and ensure no ovarian tissue has been left behind.
- The contralateral ovary can be removed in the same manner.

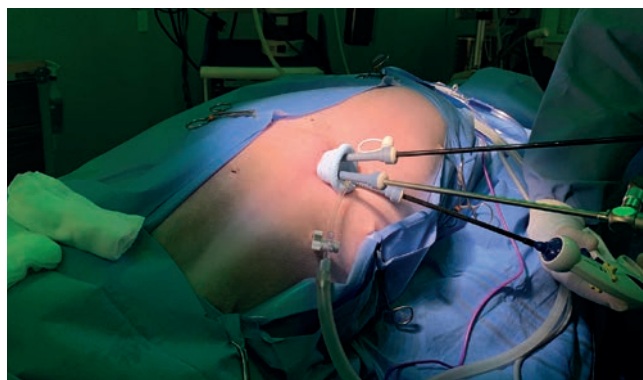


FIGURE 25. Placement of the SILS port on the umbilicus for a laparoscopic ovariectomy. This instrument arrangement utilizes a 30° telescope, an articulating grasper and a bipolar vessel-sealing device.

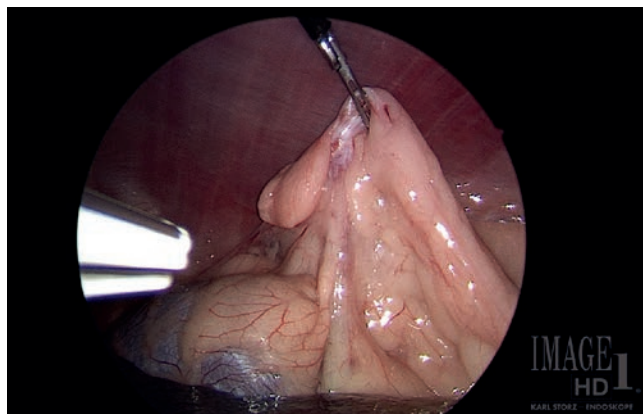


FIGURE 26. Left proper ligament being suspended to enable proper vascular pedicle exposure for the vessel-sealing device.

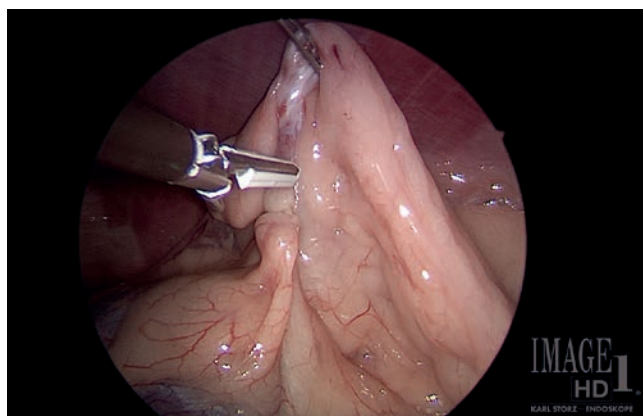


FIGURE 27. Bipolar vessel-sealing device dissecting the pedicle.

- After removing the single-port device, the small incisions in the abdominal fascia and in the skin at the portal sites are closed routinely (**Fig. 29**).

POSTOPERATIVE MANAGEMENT

- Most patients have short general anesthesia times and recover rapidly after surgery.
- Patients that are considered stable and healthy preoperatively can typically be discharged on the same day.
- For lapOVE without concomitant pathologies antibiotic therapy is not necessary.
- Local analgesics at the time of incision site closure is recommended. Analgesia is continued for a few days after surgery.
- Restricted exercise for 3–4 days after surgery.

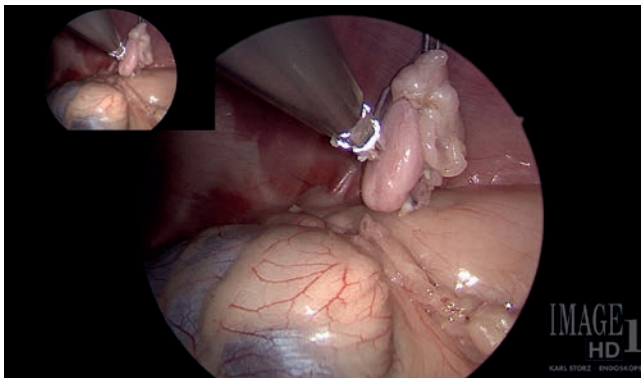


FIGURE 28. Left pedicle fully free from its vascular attachments.

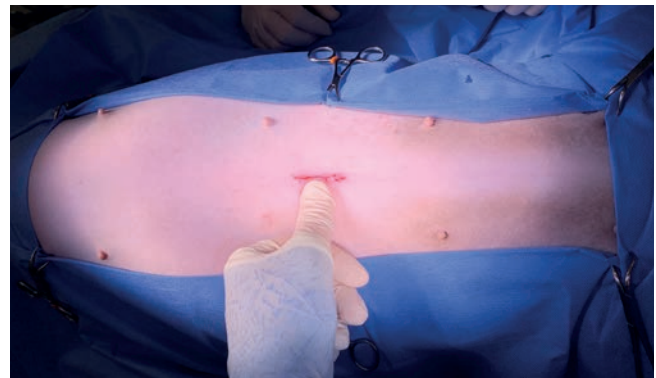


FIGURE 29. Postoperative view of the incision at the umbilicus.

Complications of lapOVE

- Low complication rates, mostly related to laparoscopic procedures.
- Hemorrhage. Bleedings from the pedicle due to incomplete closure of the vascular structures.
- Conversion to laparotomy rates are very low and due to iatrogenic lesions to the spleen, hemorrhage, or dropping and loss of the ovary in the abdomen.
- Acquired urinary incontinence, as a benign condition, has been reported to occur in 9% to 15% of cases.
- Retained ovarian tissue.

Key points

- Tilt the patient 30°/45° for better visualization of the ovaries.
- Use a VSD.
- In case of ovarian pathologies, perform an OVH.



SUGGESTED READINGS

CLINICAL CASES

15.1 OVARIECTOMY BY TRANSVAGINAL TOTAL NOTES

Maurício Veloso Brun, Marco Augusto Machado-Silva

CASE DESCRIPTION

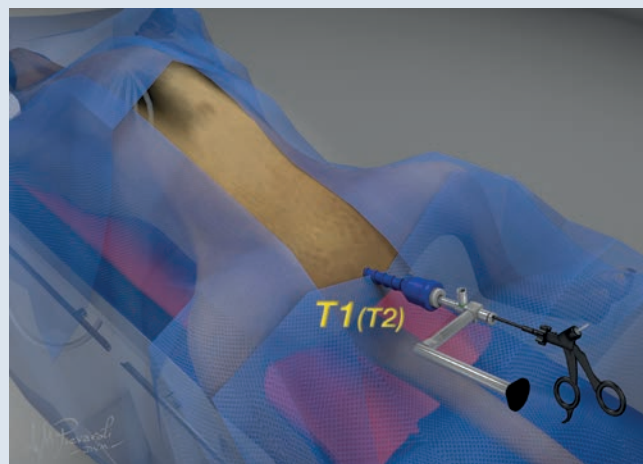
Transvaginal total NOTES (natural orifice transluminal endoscopic surgery) is an interesting approach for ovariectomy in dogs. Total NOTES ovariectomy does not require abdominal access and postoperative wound care, as the access is performed through a single transvaginal port. Female dogs with a large amount of fatty tissue surrounding the ovaries are poor candidates, since the vaginal wound is relatively small (about 11–13 mm) and retrieving the ovaries may be extremely difficult. The length of the peritoneal cavity and diameter of the vaginal lumen may also be limiting factors.

Key points

- The vaginal cavity and vulva are flushed with chlorhexidine (0.05%) or povidone-iodine (0.1%) solution (10 mL/kg). The bladder should be drained through a catheter, which should be left in place throughout the surgery.
- Using 4 thin-tipped Kelly or Crile forceps, the vaginal mucosa should be grasped and pulled until the fornix is exposed through the vulva.

PORT PLACEMENT

Due to the limited reach of the operative endoscope and laparoscopic instruments, transvaginal total NOTES ovariectomy is indicated for selected patients.



PROCEDURE

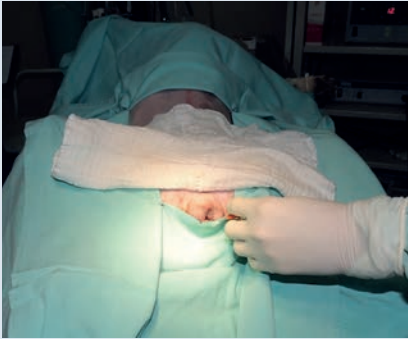

FIGURE 1. The patient is placed in dorsal recumbency, with the head directed towards the video system, with wide exposure of the abdomen and vagina. A wide area of abdominal and perineal hair is clipped, including the paralumbar fossa and caudal third of the rib cage up to the transverse processes, in addition to the inner aspect of the hindlimbs.

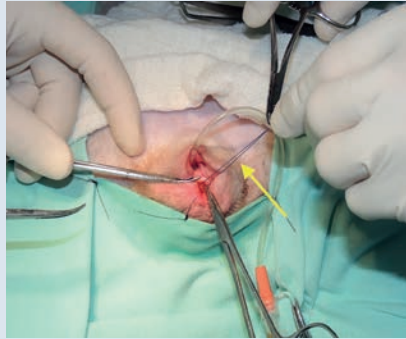


FIGURE 2. A tacking suture is placed in the mucosa of the fornix in a ventral position (arrow); it will be critical for vaginal wound closure at the end of the procedure. Using fine-tipped curved hemostats, the fornix area is grasped and exteriorized for placement of the tacking suture, which is further used to expose the vaginal wound.

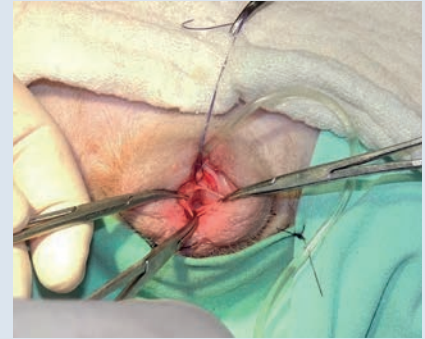


FIGURE 3. An incision is made in the vaginal mucosa and submucosa. The remaining layers of the vagina will be bluntly dissected using the rounded trocar tip until the abdominal cavity is reached. Hemostatic forceps are used to grasp the edges of the vaginal wound to guide trocar insertion.

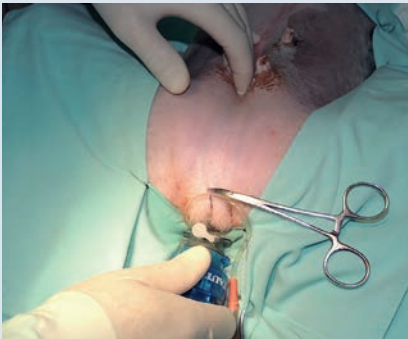

FIGURE 4. A disposable translucent 10–12 mm smooth trocar cannula with a blunt obturator is inserted through the vaginal wound in order to perforate the remaining layers by blunt dissection, thus providing access to the peritoneal cavity.

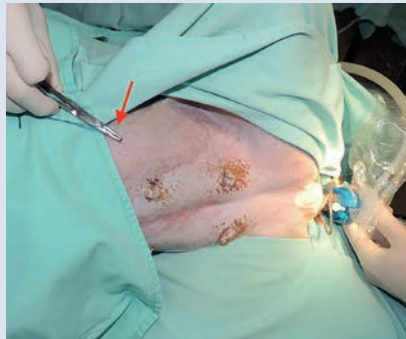

FIGURE 5. A 10 mm straight-angled operative laparoscope is inserted through the cannula to confirm complete access to the abdominal cavity. Long (≥ 38 cm of working length) 5 mm laparoscopic Kelly forceps are used to grasp the uterine horn at the level of the proper ovarian ligament. With the patient slightly rotated, the ovary is raised and attached to the abdominal wall using a transparietal suture (arrow) for exposure of the mesovarium.

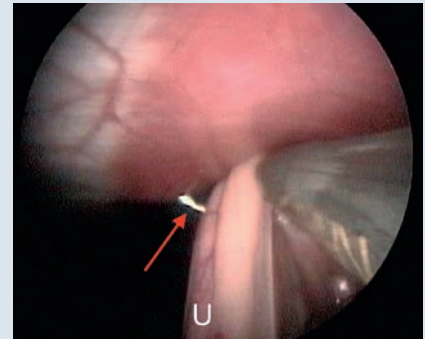


FIGURE 6. The uterine horn (U) is raised to the abdominal wall and a transparietal suture is placed using a long thread. Laparoscopic view of the transparietal suture (arrow) used to expose the ovary and its ligaments and vessels.

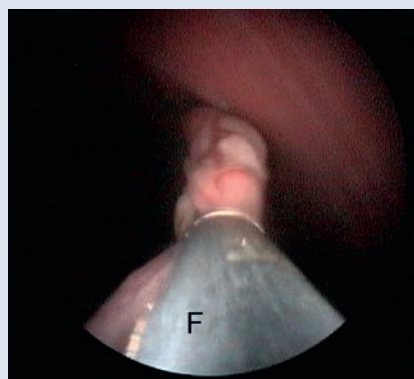


FIGURE 7. Bipolar forceps (F) with a cutting blade and a vessel-sealing device or ultrasonic scalpel should be used to coagulate and transect the uterine horn and vessels as close as possible to the proper ligament. Transection of the uterine horn is performed close to the proper ligament.

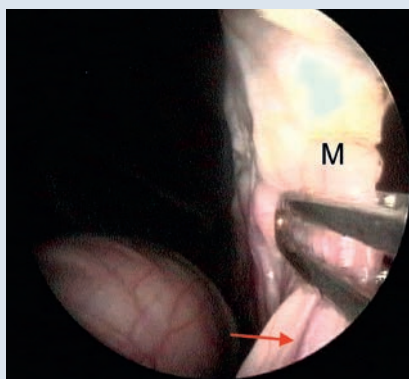


FIGURE 8. The ovarian pedicle, mesovarium and suspensory ligament are subsequently coagulated and severed, until the ovary is completely released. Coagulation of the vessels of the ovary and mesometrium (M). The arrow highlights the left ovarian vein.

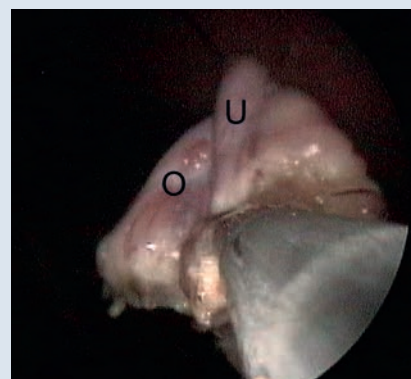


FIGURE 9. The ovary is removed from the cavity while keeping the transparietal suture anchored to it. If the cannula is removed along with the ovary, it should be replaced to approach the opposite ovary. The isolated ovary (O) will be inserted through the vaginal cannula. The ovary should be grasped at the level of the remaining uterine horn (U) or suspensory ligament.

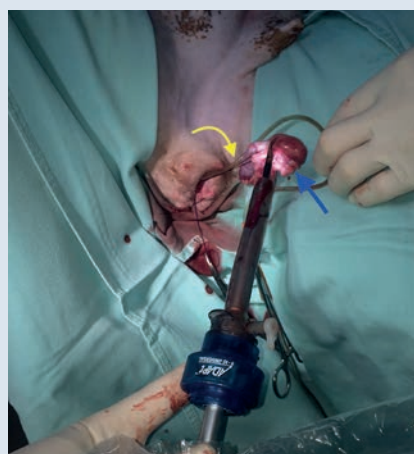

FIGURE 10. Removal of the ovary (blue arrow) along with the cannula and Kelly forceps from the abdominal cavity. The transparietal suture (yellow arrow) is still attached to the ovary.

Tips and tricks

- ✓ Transvaginal access is performed in the fornix, preferably at the midpoint of the vagina. The incision will extend to the submucosa and the vaginal tunica muscularis by blunt dissection. This provides better cannula fixation, reducing CO₂ leak.
- ✓ “Blind” insertion of the port must be cautiously performed. The colon should be pulled laterally using the surgeon’s nondominant hand while directing the cannula parallel to the ventral midline, into the peritoneal cavity.
- ✓ The use of a translucent cannula is useful for checking proper positioning of the port within the peritoneal cavity prior to insufflation.
- ✓ The authors prefer approaching the left ovary first, which is less exposed due its proximity to the spleen and colon. Tilting of the patient to the side opposite to that of the approached ovary will displace the bowel away from the ovary in cases of difficult exposure.

- ✓ The transperitoneal suture can include the proper ovarian ligament, the area below it (in this perspective) or even the uterine horn (taking care to avoid the uterine vessels). Thus, the final aspect of the horn will be adequately exposed.
- ✓ Coagulation and transection of a short segment of the uterine horn, followed by coagulation and transection of the uterine vessels and mesometrium will simplify the approach to the mesovarium, ovarian vessels and suspensory ligament. Those structures will be exposed almost in a “straight line” ahead of the forceps.
- ✓ After transection from all attachments, the ovary is grasped at the remaining uterine stump or suspensory ligament, without releasing the transperitoneal suture.
- ✓ The ovary should be brought to the cannula and preferably retrieved through it (if the size of the ovary allows it), without removing the transperitoneal suture (which remains grasped outside the cavity with a hemostat).
- ✓ The transperitoneal suture should be removed only when the ovary is completely outside the vagina. This way, if the ovary drops during removal, it will be repositioned in the flank by the external traction of the suture thread.
- ✓ The traction of the vaginal repair suture will allow adequate exposure of the wound, which will be sutured in its mucous and submucosal layers.

15.2 TWO-PORT LAPAROSCOPIC OVARIECTOMY IN THE CAT

Antoine Adam

CASE DESCRIPTION

LapOVE is a minimally invasive procedure that is commonly performed not only in dogs but also in cats. In fact, cats often recover surprisingly quickly from lapOVE. It should be noted that special surgical equipment for small-sized patients is necessary.

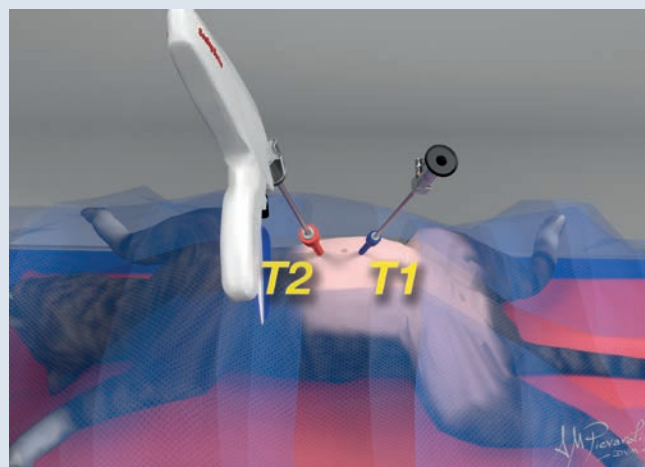
Key points

- Pneumoperitoneum is established with an 18-gauge needle at the tip of the CO₂ line.
- A 5 mm cannula is used for the cranial port, to introduce the VSD and remove the ovary.
- A 3 mm cannula is used for the caudal port, to introduce a small (3 mm) telescope.
- Light cannulas should be used.
- The telescope is placed near the region of interest to achieve good visualization (3 mm telescopes have less light).
- The fat is dissected before placing the 3 mm cannula to help with closure and avoid future herniation.

PORT PLACEMENT

A small towel is placed under the back of the cat to elevate the abdomen. A heating mat and, if needed, a ground plate for electrosurgery should also be placed.

The first cannula (T1) is placed on the midline, approximately 1–2 cm caudal to the umbilicus, and a 3 mm camera is introduced. The second cannula (T2), for the 5 mm VSD, is placed on the midline, approximately 2 cm cranial to the umbilicus.



PROCEDURE

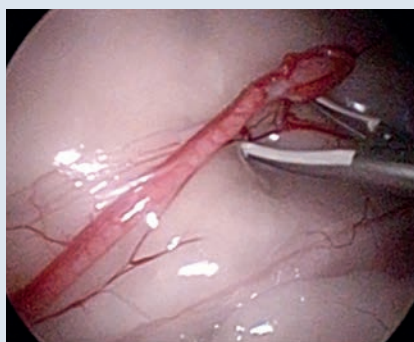


FIGURE 1. Dissection of the ovarian vessels. The ovary is located at the caudal pole of the kidney. No traction device is needed. The goal is to place the tip of the vessel-sealing device underneath the ovarian vessels.

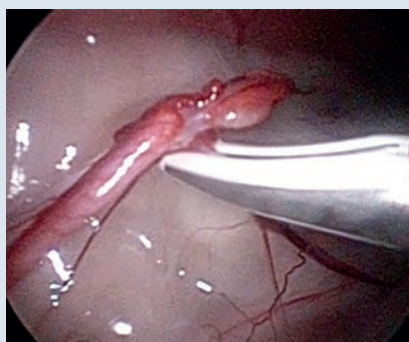

FIGURE 2. Under good visual control, the ovary is suspended with the tip of the vessel-sealing device, and the ovarian vessels are cut.

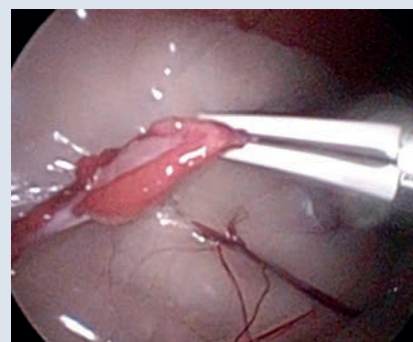

FIGURE 3. The suspensory ligament is cut in the same manner. Care should be taken to ensure that all the ovary is removed.

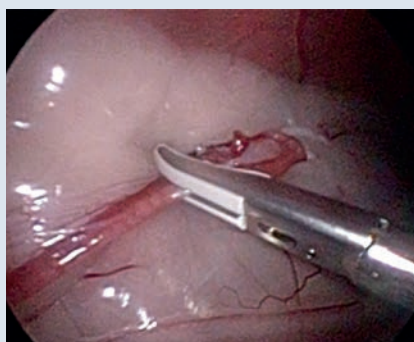

FIGURE 4. After cutting the uterine horn, the ovary is left in place. The vessel-sealing device is replaced with a 5 mm Babcock forceps, which is used to grab the ovary. If there is any tissue still holding the ovary, gentle traction is applied to tear it.

Tips and tricks

- ✓ Use an 18-gauge needle, not a Veress needle, to create the pneumoperitoneum.
- ✓ Do not use three portals. Use the VSD to seal and dissect the ovaries.
- ✓ An abdominal insufflation pressure of 6–8 mmHg is enough.
- ✓ Use the tip of the VSD to retract the spleen (if it obscures the view of the left ovary) by grabbing the fat and the vessel at the hilus.
- ✓ Dissect the fat before placing the 3 mm cannula to help with closure.

15.3 LAPAROSCOPIC OVARIECTOMY IN A DOG WITH TYPE III SCLEROSING ENCAPSULATING PERITONITIS

Michael Brückner

CASE DESCRIPTION

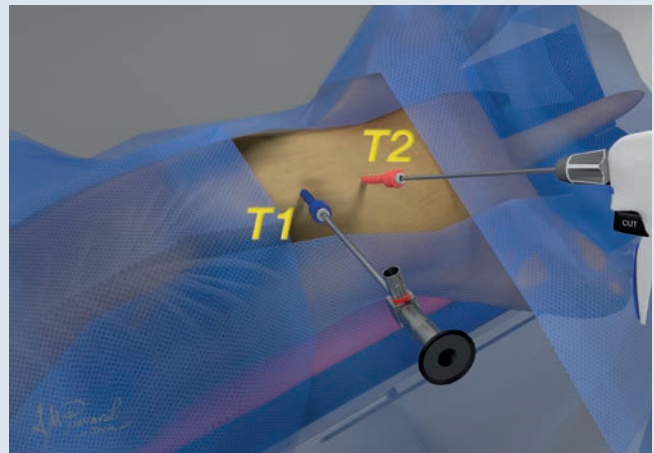
A 14-month-old intact female mixed-breed dog was diagnosed with type III sclerosing encapsulating peritonitis (SEP) at the age of 5 months after a routine workup including biopsy performed during exploratory laparotomy. About 1 year later the owner wanted to spay her dog and an OVE was recommended, especially due to the presence of extensive adhesions. A laparoscopic approach was chosen to reduce the amount of intraoperative tissue manipulation and inflammation as well as to minimize the size of the incision, as the dog was on prednisolone treatment. A standard two-port approach was chosen and dissection of the adhesions reduced to a minimum. Both ovaries were temporarily fixated with a percutaneous needle–suture combination and transected using a VSD.

Key points

- Minimal tissue manipulation keeps inflammation low.
- Blunt dissection avoids further inflammation.
- The use of percutaneous suspension reduces the number of ports.

PORT PLACEMENT

A 6 mm Ternamian Endotip trocar was placed in the umbilicus (camera port), and an 11 mm cannula with multifunction valve was placed half-way between the umbilicus and the pubic rim. The patient was tilted to the right and left sides to reach the respective contralateral ovaries.



PROCEDURE

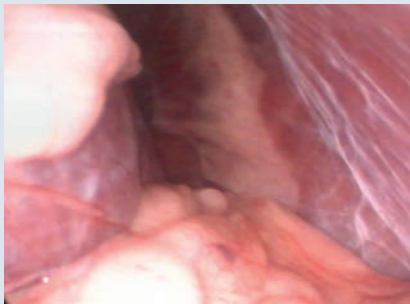

FIGURE 1. Transition between the abdominal wall and diaphragm. Multiple fibrin strands are visible over the peritoneum. The stomach and spleen are enclosed in a sac of fibrous tissue.

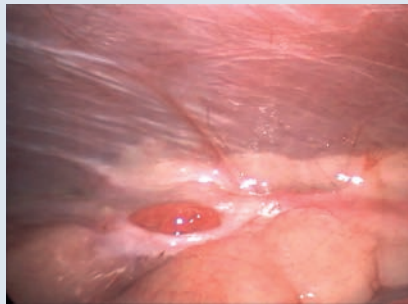


FIGURE 2. The left bursa ovarica is visible as well as the fibrin strands on the peritoneal lining of the abdominal wall.

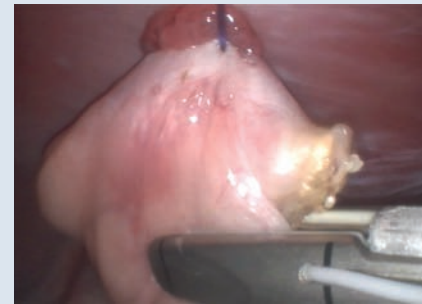

FIGURE 3. The left ovary is temporarily suspended from the abdominal wall with a needle-suture combination, and the uterine horn is transected with a vessel-sealing device.

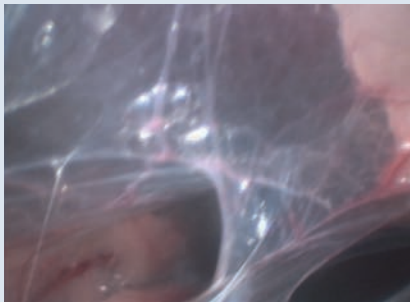


FIGURE 4. Multiple adhesions between the organs prevent the visualization of the right ovary.

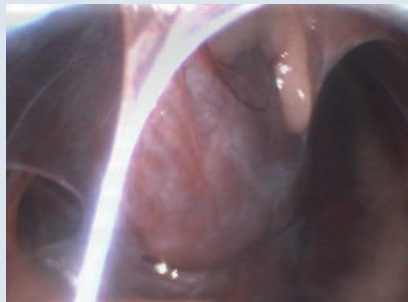

FIGURE 5. The urinary bladder is attached to the ventral abdominal wall and has multiple adhesions around.

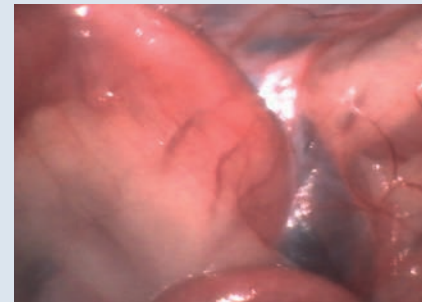

FIGURE 6. The camera is switched to the caudal port, and the adhesions between the small intestinal loops are partially dissected with the grasping forceps.

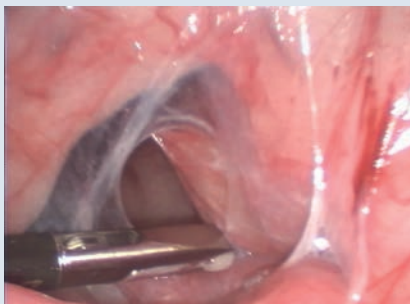

FIGURE 7. The camera is switched back to the cranial port. The small intestinal loops are further dissected to allow visualization of the right ovary.

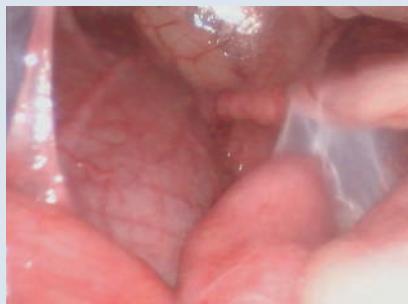

FIGURE 8. Further adhesions between the urinary bladder, uterus, and small intestinal loops, allowing classification as type III sclerosing encapsulating peritonitis.

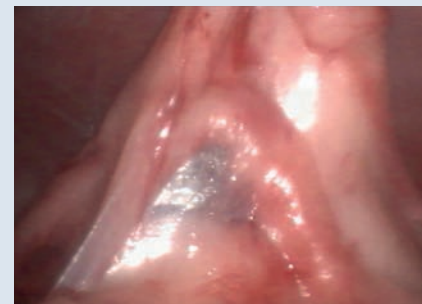

FIGURE 9. The right ovary is percutaneously attached to the abdominal wall. A small intestinal loop is adhered to the mesometrium. The suspensory ligament is to the right of the image.

Tips and tricks

- ✓ Use gravity to your advantage.
- ✓ Switch between ports.

- ✓ Use a VSD.

15.4 LAPAROSCOPIC OVARIECTOMY IN LARGE- AND GIANT-BREED DOGS

Paolo Boschi, Roberto Properzi

CASE DESCRIPTION


One of the complications associated with lapOVE in large- and giant-breed dogs is the difficulty of removing the ovary through the operating cannula due to its large size. This complication increases surgical time and the risk of ovarian tissue rupture. To facilitate ovary removal, it is recommended to transect the ovarian bursa with a bipolar VSD and remove the ovarian tissue without the ovarian bursa through the operating portal.

Key points

- One of the complications of lapOVE in large- and giant-breed dogs is the difficulty of removing the ovary through the operating cannula.
- In large- and giant-breed dogs, the ovarian tissue should be separated from the ovarian bursa and removed through the operating cannula.

PORT PLACEMENT

A standard three-midline-ports laparoscopic approach was used. The first cannula (T1) was placed 1–2 cm cranial to the umbilicus and a 10 mm 30° telescope was introduced. A 5 mm cannula (T2) was placed 4 cm caudal to T1. A 10 mm cannula (T3) was placed 4 cm caudal to T2.



PROCEDURE

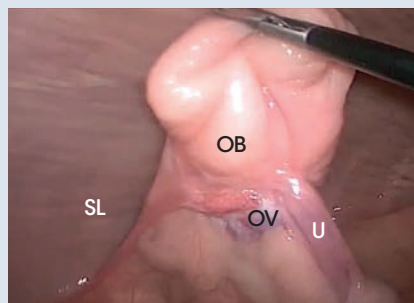


FIGURE 1. The ovarian bursa (OB) is grasped and pulled using laparoscopic Babcock forceps. Note the ovarian vessels (OV), uterus (U), and suspensory ligament (SL).

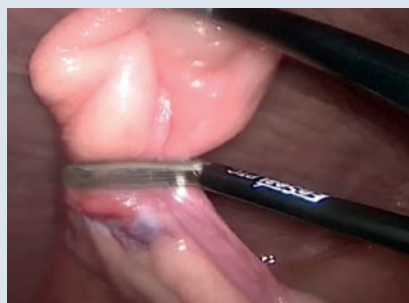


FIGURE 2. The ovarian bursa is transected using a bipolar vessel-sealing device. It can be partially or completely transected.

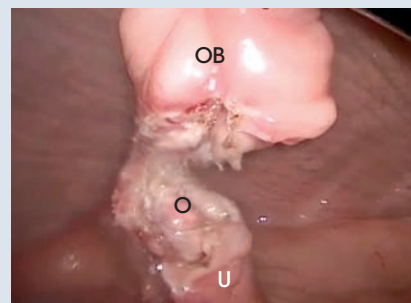

FIGURE 3. Ovarian bursa (OB) partially transected. O, ovary; U, uterus.

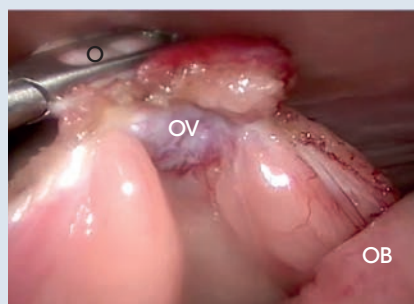


FIGURE 4. The ovary (O) is grasped with the laparoscopic Babcock forceps. Note the transected ovarian vessels (OV) and ovarian bursa (OB).

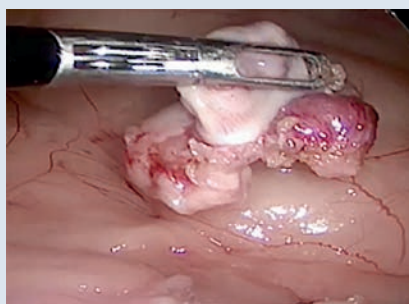


FIGURE 5. The ovary is freed from the ovarian bursa with a gentle rocking motion and is easily extracted from the abdomen through the 10 mm operating cannula.

Tips and tricks

- ✓ Transect the ovarian bursa to make ovary removal easier in large- and giant-breed dogs.
- ✓ Gently pull the freed ovary, without the ovarian bursa, through the operating cannula and out of the abdomen.

15.5 TWO-PORT LAPAROSCOPIC OVARIECTOMY WITHOUT OVARY SUSPENSION SUTURE IN A FEMALE DOG

Giovanni Allevi

CASE DESCRIPTION

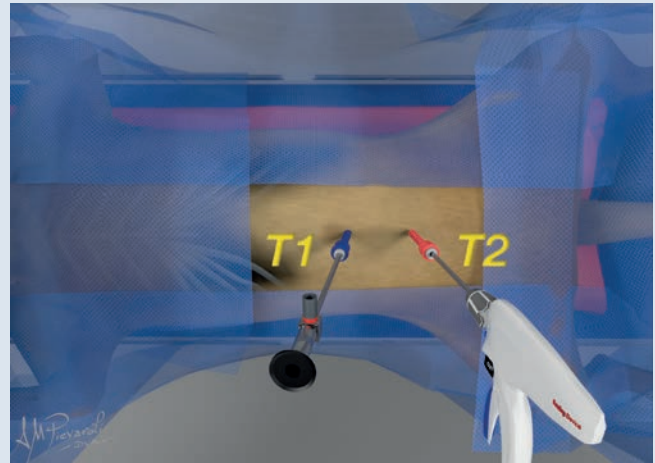
A new lapOVE technique has been evaluated in 50 female dogs. This technique is performed using only two ports, with no suspension of the ovaries.

Key points

- This technique does not involve suspension of the ovary using a transabdominal suspension suture with a round needle or forceps.
- It is important to check for any uterine condition to evaluate the need for an OVH.

PORT PLACEMENT

The patient was placed in dorsal recumbency for setting up the operating field: a two-port technique with two 5 mm trocars was performed (VersaPort, Covidien). The first cannula (T1) was placed 1 cm caudal to the umbilicus with a modified Hasson technique and a 5 mm 30° telescope (Karl Storz Veterinary Endoscopy) was introduced; the abdomen was inflated with carbon dioxide (CO₂) with a pressure of 10 mmHg. The second cannula (T2) was placed on the midline, a few centimeters caudal to T1.



PROCEDURE

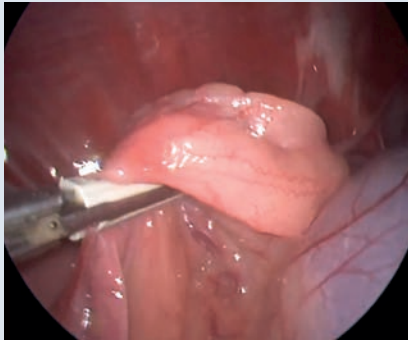


FIGURE 1. The ligation device suspends the ovary and moves it away from the abdominal wall and the other organs in a safe position.

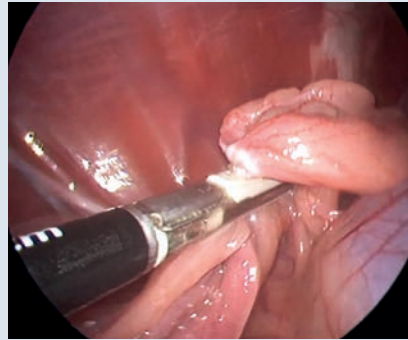


FIGURE 2. Continuous cranial sliding of the laparoscopic ligation device – ovarian ligament.

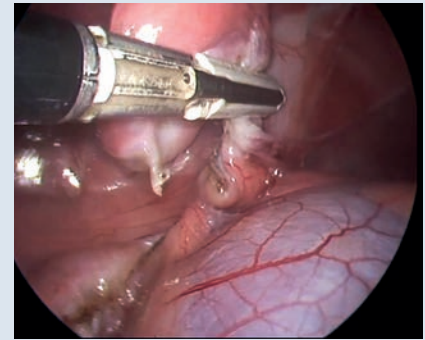


FIGURE 3. Continuous cranial sliding of the laparoscopic ligation device – suspensory ligament.

Tips and tricks

- ✓ During the use of the ligation device, a proper distance from the abdominal wall is essential in order to avoid causing injuries or pain to the patient.
- ✓ The procedure consists in a constant progression of the laparoscopic ligation device along the tissue and a continuous switching between cauterization and cutting.

15.6 LAPAROSCOPIC OVARIECTOMY IN AN AFRICAN LIONESS (*PANTHERA LEO*) USING A SINGLE-PORT MULTIPLE-ACCESS DEVICE

Mathieu Manassero

CASE DESCRIPTION

A 22-month-old lioness weighing 100 kg was presented for elective OVE for breeding control. After suitable immobilization, a catheter was placed in the cephalic vein and intravenous propofol (titrated to effect) was given to facilitate intubation. Anesthesia was maintained by sevoflurane in 100% oxygen delivered via the orotracheal tube. Electrocardiography, capnography, pulse oximetry, esophageal temperature, noninvasive blood pressure, and respiratory rate were monitored during anesthesia. The lioness was placed on a mechanical ventilator throughout the surgical procedure with an end-tidal CO₂ between 35 and 40 mmHg and a maximal airway pressure of 20 cmH₂O.

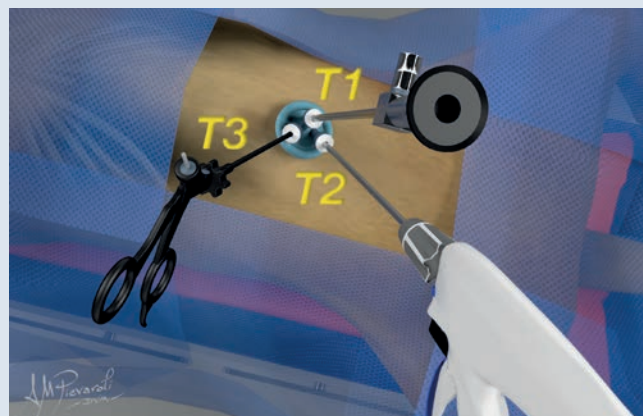
Key points

- Because of the depth of subcutaneous fat, extensive subcutaneous dissection was necessary to insert the single-port multiple-access device.
- The single-port multiple-access device was placed cautiously under visual control to avoid causing lesions and damage to abdominal organs.
- Traction on the muscular margins was maintained during insertion of the cannula to provide counter pressure and avoid iatrogenic lesions.
- After single-port device introduction, the lioness was put in a 10° Trendelenburg position and the operating table tilted at a 15° angle approximately on the right side for the left ovary and the left side for the right one to enhance exposure.
- Specific bent or articulated instruments are not necessary to perform an OVE.
- The single-port device and the first transected ovary should be removed before performing the contralateral OVE to prevent any loss of the ovary in the abdomen.
- The skin was closed with an intradermal continuous suture pattern.

PORT PLACEMENT

A single-port multiple-access technique was used with the SILS Port (Covidien, Norwalk, CT, USA). The lioness was positioned in dorsal recumbency and the abdominal area was aseptically prepared. A 2 to 3 cm skin incision was made just caudal to the umbilicus and carried down to the peritoneum.

After introduction of the single-port device, a pneumoperitoneum (12 mmHg) was induced using CO₂ through the specific cannula of the device.



PROCEDURE

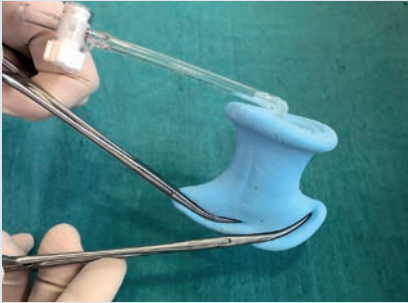

FIGURE 1. The single-port device is folded at the level of the lower ridge with the use of two curved forceps, which clamp the device in a staggered fashion.

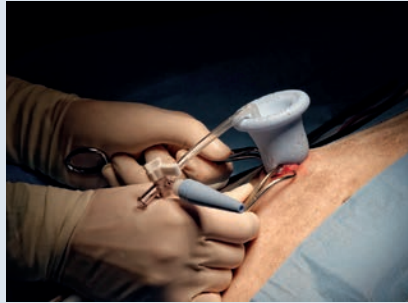

FIGURE 2. The muscular margins of the incised linea alba are grasped and everted with Babcock forceps. The lower ridge of the single-port device is subsequently introduced into the abdomen and then released from the forceps.




FIGURE 3. Three 5 mm cannulas are introduced through the access channels with a blunt trocar, which is subsequently withdrawn, and the pneumoperitoneum (12 mmHg) is induced.

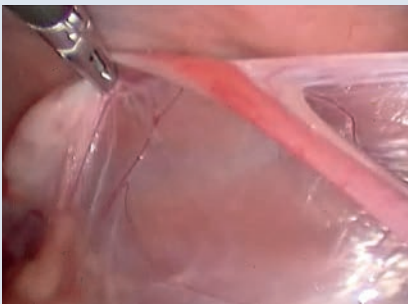


FIGURE 4. The table is tilted to the right side to expose the left ovary. The proper ligament is then grasped and suspended using a standard 5 mm laparoscopic grasper.

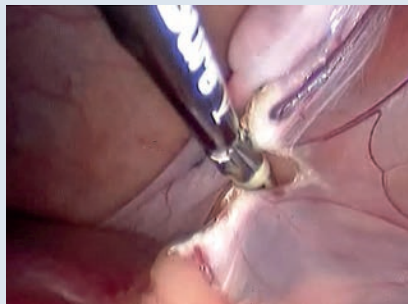

FIGURE 5. The proper ligament is pulled caudally and the ovarian pedicle is sealed and transected first with a 5 mm laparoscopic vessel sealer/divider device.

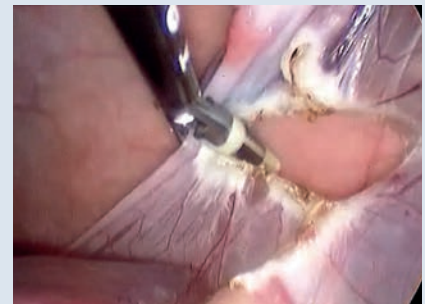

FIGURE 6. The cranial part of the mesovarium is subsequently sealed and transected to the suspensory ligament with the vessel sealer/divider device while moving the ovary caudally.

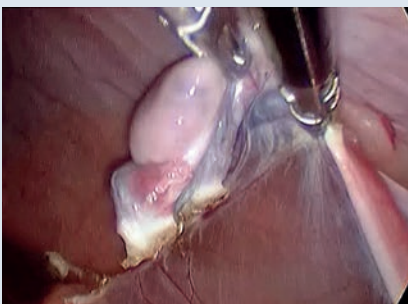


FIGURE 7. Finally, the proper ligament is pulled cranially and the proximal part of the uterine horn and caudal part of the mesovarium are sealed and transected with the vessel sealer/divider device while moving the ovary cranially.

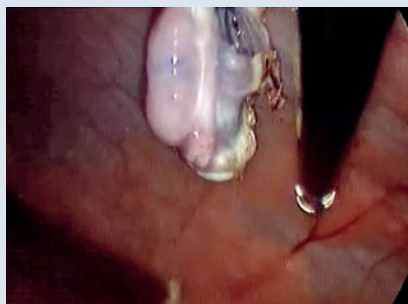


FIGURE 8. While the transected left ovary is firmly grasped with the laparoscopic grasper, the vessel sealer/divider device, the telescope, single-port device, and associated cannulas are removed and the grasper and ovary are subsequently retrieved from the abdomen. The single-port device is reintroduced as previously described and the right ovariectomy is performed in the same way.

Tips and tricks

- ✓ The muscular margins of the incised linea alba can be grasped with stay sutures (0 polyglactin 910) instead of Babcock forceps to provide more working space for single-port device insertion.
- ✓ To increase maneuverability and decrease potential conflict between the instruments and telescope, the use of a 30° telescope and a right-angle adaptor placed onto the connection between the light cable and telescope is advised.
- ✓ Place the telescope port in the most lateral and upper access of the single-port device. To accommodate this position the single-port device can easily be rotated after its insertion.
- ✓ Do not hesitate to switch the position in the single-port device of the laparoscopic grasper and the vessel sealer/divider device to increase safe use of the vessel sealer/divider device.
- ✓ Use of 43 to 45 cm long laparoscopic instruments is advised in lionesses.
- ✓ Apply the vessel sealer/divider device as close as possible to the ovary and uterine body to avoid causing damage to a large mesometrial vessel or ureter.
- ✓ For device removal, remove first the cannula, which allows the abdomen to deflate, relieves pressure on the muscular edges of the laparotomy incision, and thus facilitates removal of the device.
- ✓ Even if this is possible, the use of a 10 mm vessel sealer/divider device into a 10 mm cannula is not advised because it reduces triangulation if specific bent or articulated instruments are not used.

15.7 LESS OVARECTOMY USING A SIMPLE HANDMADE ACCESS DEVICE

Marco Augusto Machado Silva, Maurício Veloso Brun

CASE DESCRIPTION


There is a growing interest towards laparoendoscopic single-site surgery (LESS) approaches in the small animal setting. Several auto-clavable and single-use LESS access devices are available. Almost all of them were developed for use in human patients and require a 2–4 cm long incision (usually at the umbilicus, for cosmetic purposes). While cosmetic appeal is not a frequent (if any) concern in small animals, decreased pain and wounds are the most important benefits reported. Limitations of LESS devices and instruments in the veterinary practice include lack of triangulation, need for expensive long curved instruments to compensate the lack of triangulation, and absence of LESS devices designed for use in small animals, especially small dogs and cats. To fill these gaps, a simple and relatively inexpensive handmade LESS access device was developed for both OVE and OVH in small dogs and cats. The main advantages of this device are use of two channels, no need for expensive operative laparoscopes, no need for curved LESS instruments, short (about 6–10 mm) incision length, works as a specimen retrieval device, quick and easy to assemble and to adjust to the abdominal wall, and provides optimal seal, avoiding CO₂ leak.

Key points

- Components of the handmade LESS device: two trocar cannulas (3–5 mm), a funnel obtained from a plastic (polyethylene terephthalate, PET) bottle, a latex balloon, two urinary catheters (8 and 12 Fr), and a 2-0 nylon thread.
- Preparation: the catheters are sterile, the latex balloon is steam sterilized, and the plastic cone should be sterilized using “cold” methods (soaking, peroxide plasma, ethylene oxide).
- Assembly of the device:
 1. Assembly a ring of 1.5–2.0 cm diameter using the 8 Fr and 12 Fr urinary catheters.
 2. Cover the funnel with the balloon.
 3. Pass the sheath of the balloon through the ring.
 4. Fold the balloon sheath backwards, covering the ring and the small hole of the funnel (a short latex sheath of about 5–10 mm must remain between the ring and the small hole of the funnel).
 5. Make two holes in the balloon, at the large hole of the funnel.
 6. Insert the two trocar cannulas through the two holes in the balloon.
 7. Attach the cannulas to the balloon with two encircling sutures. The device is ready for use.

PORT PLACEMENT

The patient and the surgical field were aseptically prepared as for two-port lapOVE, including clipping of the paralumbar area. A 6–10 mm midline celiotomy was performed 1–3 cm caudal to the umbilicus. The ring of the handmade device was inserted through the abdominal incision, leaving the funnel outside the abdominal cavity. At this point, the device will seem locked inside the abdominal cavity, as the ring reexpands when released within the cavity and the sheath of the device is short enough to keep the abdominal wall trapped between the ring and the small hole of the funnel. The CO₂ cable was connected to the valve of one of the cannulas for abdominal insufflation. The telescope and an instrument were inserted through the cannulas.



PROCEDURE

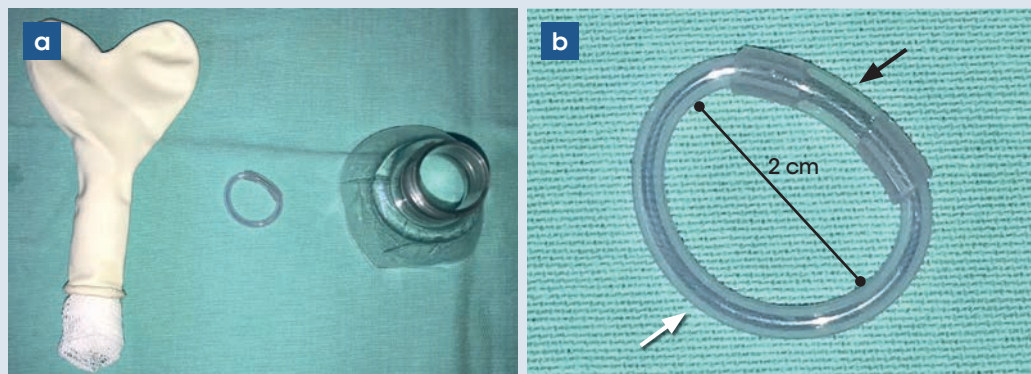


FIGURE 1. Components of the handmade LESS access device. a) Left: a heart-shaped latex balloon. Middle: a ring made from 8 Fr and 12 Fr urinary catheters. Right: a funnel obtained from a plastic (PET) bottle. b) Detail of the catheter ring. A piece of a 12 Fr catheter (black arrow) is coupled to a piece of an 8 Fr catheter (white arrow). Inner diameter of 2 cm.

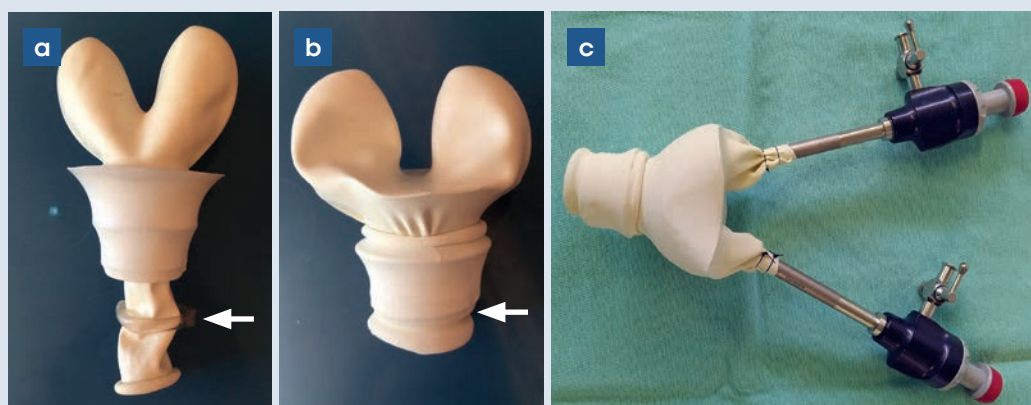


FIGURE 2. Assembly of the handmade LESS access device. a) The plastic funnel is covered by the latex balloon. The sheath of the balloon is passed through the catheter ring (arrow). b) The sheath of the balloon is folded backwards to cover the ring and the small hole of the funnel. A short sheath (arrow) remains between the ring and the small hole of the funnel. c) Device ready for use.

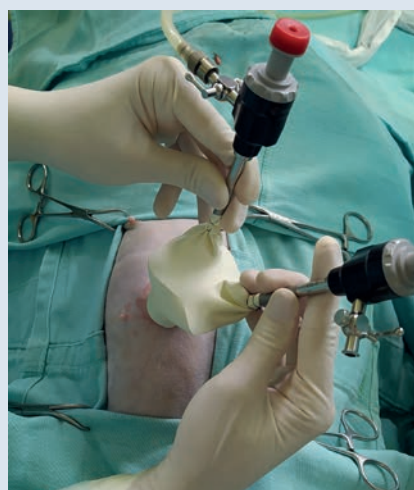


FIGURE 3. The handmade LESS access device in the abdominal cavity of a cat (bottom of image, caudal; top of image, cranial). Note the CO₂ cable attached to the valve of the most cranial cannula.

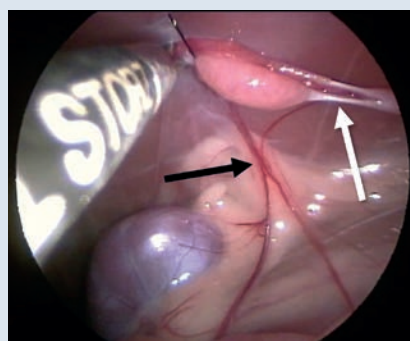


FIGURE 4. The operating table is tilted laterally to the right side to expose the left ovarian pedicle, as traditionally performed in the two-port lapOVE approach. The ovary is lifted against the abdominal wall using grasping forceps and a tacking suture is applied to the suspensory ligament. Note the wide exposition of the ovarian pedicle (black arrow) and proper ligament (white arrow).

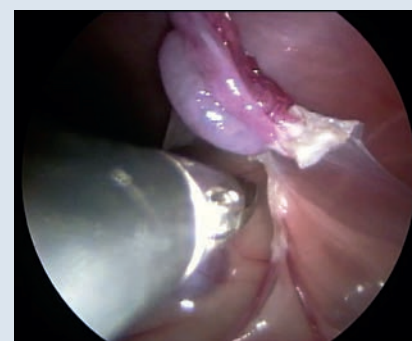

FIGURE 5. Bipolar forceps with a cutting blade (or vessel-sealing device or ultrasonic scalpel) are used to coagulate and transect the uterine horn and vessels as close as possible to the proper ligament. Then, the ovarian pedicle and suspensory ligament are coagulated and transected.

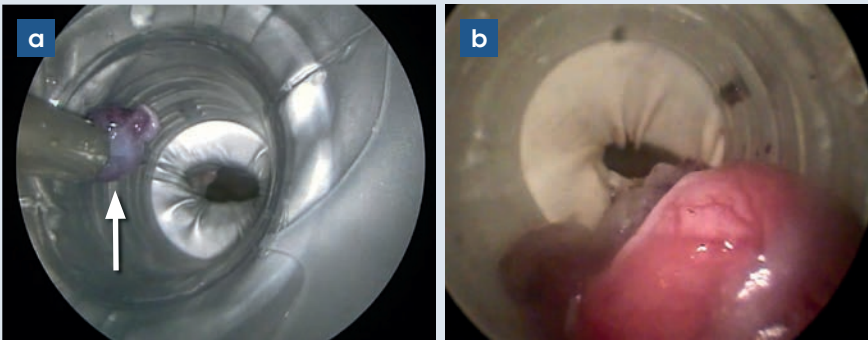


FIGURE 6. The ovary is grasped by the suspensory ligament, uterine horn stump, or proper ligament, and the tacking suture is released. a) The ovary (arrow) is retrieved through the cannula of the device. The contralateral ovary is removed in the same manner. The device is retrieved by gentle traction and the wound is closed routinely. b) Large ovaries, like the one shown in the image (from a dog), can be stored inside the device for further retrieval after resection of both ovaries.

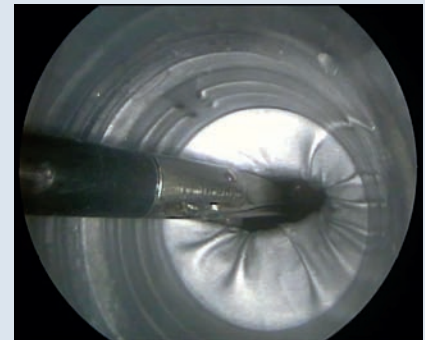


FIGURE 7. Instrument switching, if required, is performed under endoscopic guidance. In the image, Metzenbaum scissors are inserted into the abdominal cavity after pulling the endoscope back into the access device.

Tips and tricks

- ✓ The funnel can be of different materials (e.g., steel, polypropylene, etc.).
- ✓ If small-diameter (≈ 3 mm) instruments, telescope, and trocars are used, the celiotomy should be shorter (≈ 6 mm).
- ✓ In cases of small umbilical hernias, access can be performed through the defect.
- ✓ Ensure that the ring of the device is correctly and completely placed through the linea alba incision, not in the subcutaneous or retroperitoneal space.
- ✓ The authors prefer to place the device so that the trocars are aligned with the patient's long axis; that is, one cannula is cranial and the other caudal.
- ✓ Preferably insert the telescope through the cranial cannula. Although some sword fighting may occur, this will make instrument motion easier, resembling the two-port lapOVE technique.
- ✓ If instrument change is necessary, pull the telescope back within the device to assist instrument entry.
- ✓ The authors prefer to grasp the suspensory ligament rather than the proper ligament or the uterine horn to lift the ovary against the abdominal wall. Thus, the transparietal suture is passed through the suspensory ligament. This provides better exposition of the proper ligament and ovarian pedicle.
- ✓ If the ovary is too large to be withdrawn through a 3–5 mm cannula, it should be released within the device. The same maneuver is then performed for resection of the contralateral ovary, and the device with both ovaries inside is finally removed.